
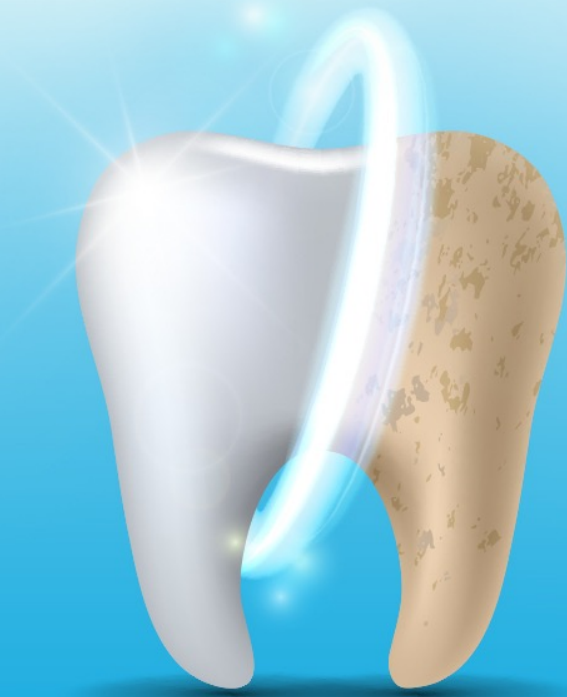


OPERATIVE DENTISTRY (LECTURE 3)

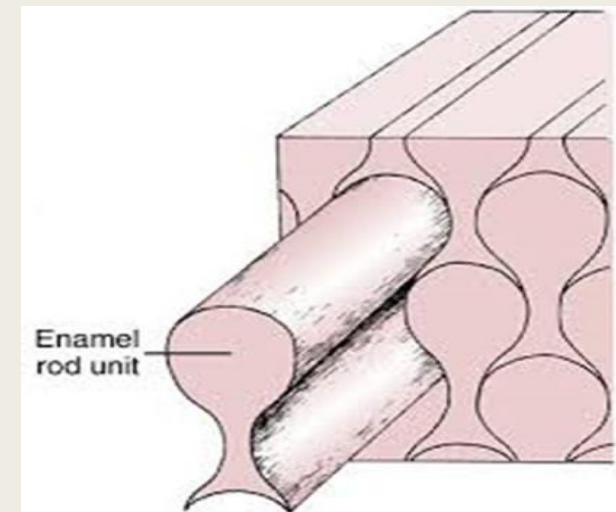
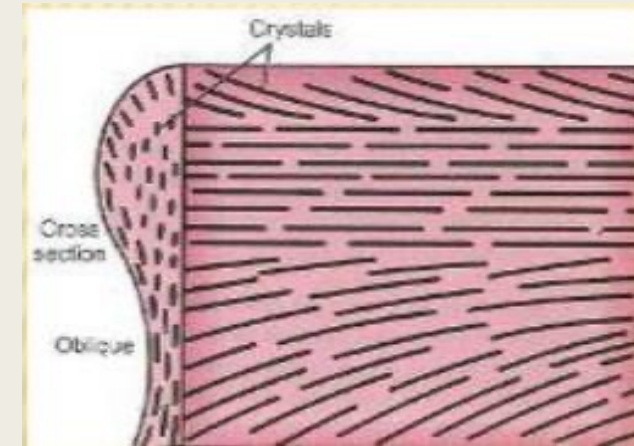
By: Dr. Yasser Hameed Edan
Master in Esthetic and Restorative dentistry
Islamic University

What is
ENAMEL?

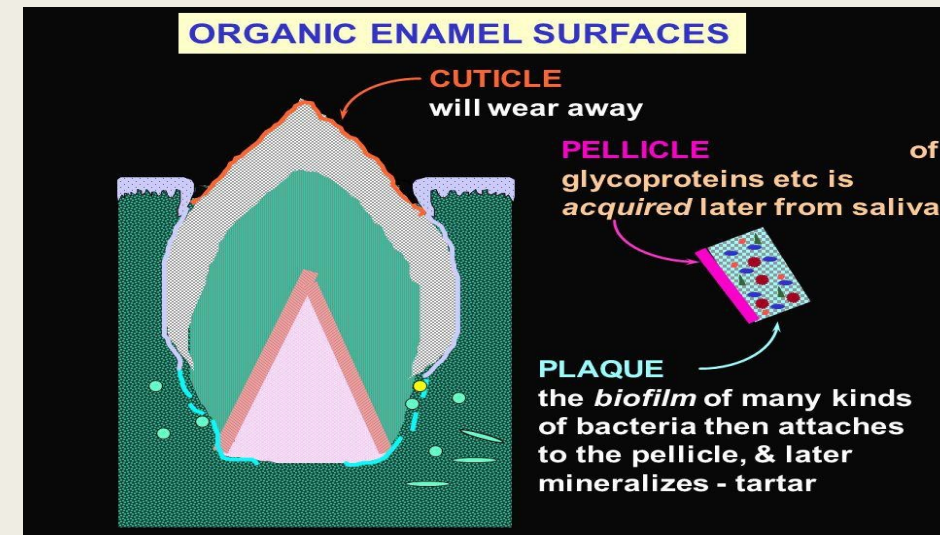


Biologic considerations of enamel and its clinical significance in operative dentistry:

- Histological view
- Enamel is formed by cells called **ameloblasts**.
- Enamel provides a **hard, durable shape** for the functions of teeth and a **protective cap** for the vital tissues of dentin and pulp.
- Enamel is incapable of repairing itself once destroyed because the ameloblast cell degenerates after formation of enamel rod.




- The final act of ameloblast cell is secretion of a membrane covering the end of enamel rod.
- This layer is referred to as **Nasmyth membrane** or the **primary enamel cuticle**, which covers the newly erupted tooth and is worn away by mastication and cleaning.
- The membrane is replaced by an organic deposit called a **pellicle**, which is a precipitate of salivary proteins.
- Microorganisms may invade the pellicle to form **bacterial plaque**, a potential precursor to dental disease.

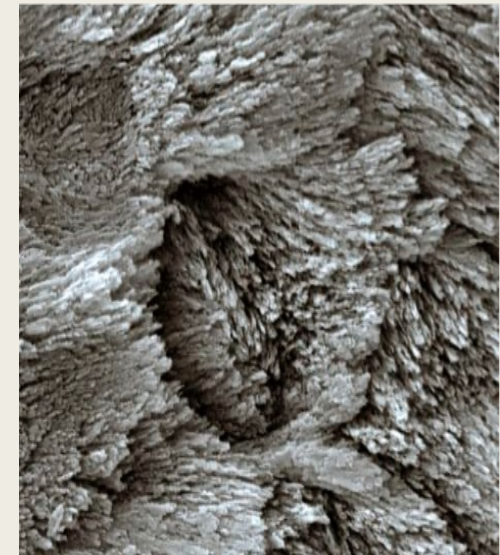



- Enamel Structure

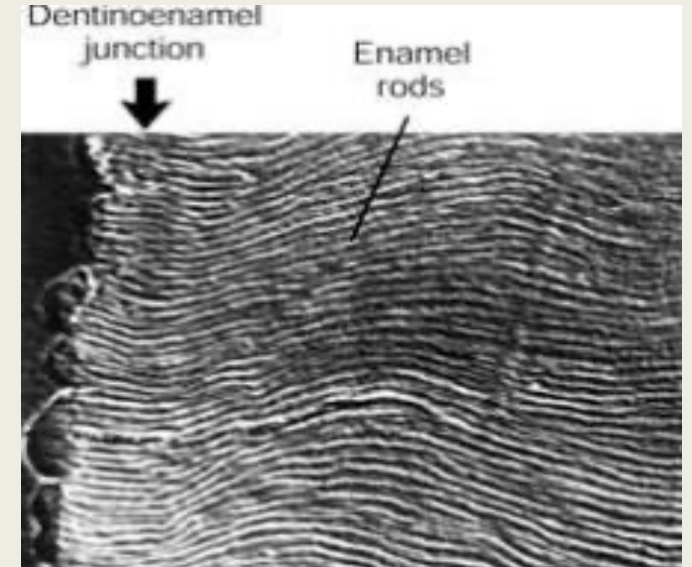

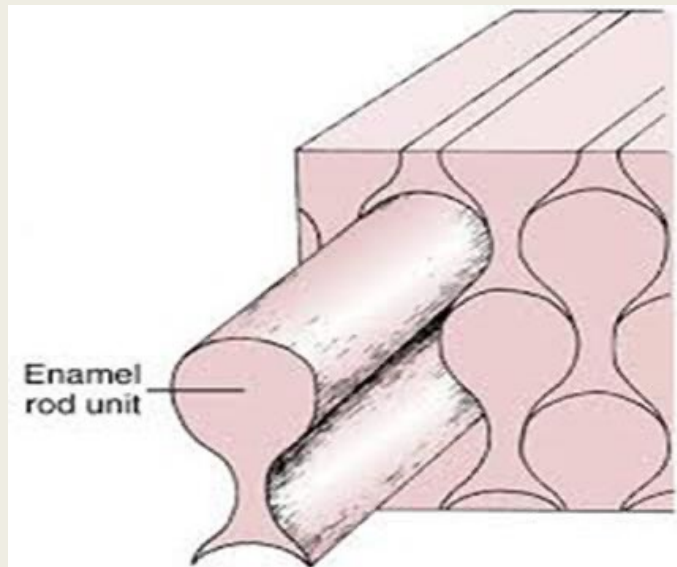
- Structurally enamel is composed of millions of **enamel rods** or **prisms**. The rods are densely packed and have a wavy course and each extends from the DEJ to the external surface of the tooth.
- E. is the **hardest** substance of human body, E. is **very brittle**, and so it requires a base of dentin to withstand the masticatory stress. Enamel rods that fail to possess a dentin base because of caries or improper cavity design are easily fracture away from neighboring rods.




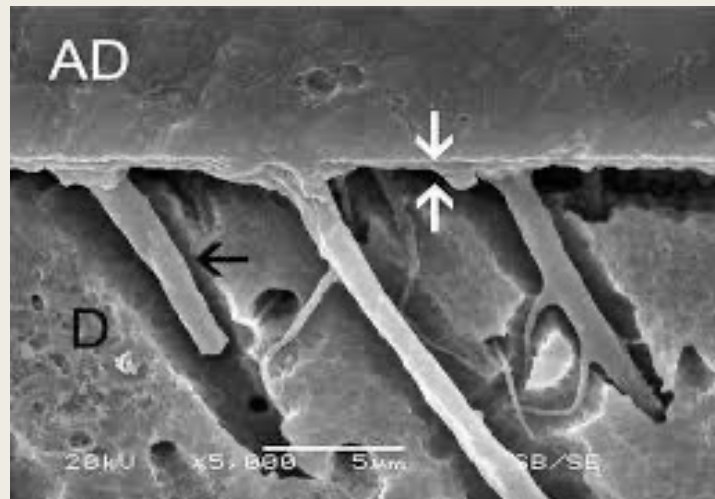

A, Its rod structure as seen in ground sections with the light microscope. B, Electron micrography shows that enamel consists of a mass of crystallites organized into rod and interrod enamel.



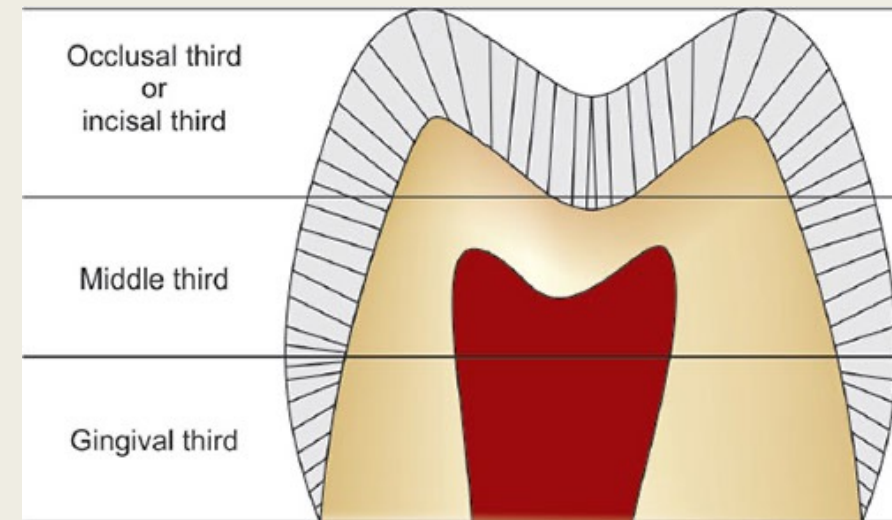
- The structural components of enamel prisms are millions of small elongated apatite crystals which are tightly packed in a distinct pattern of orientation that gives strength and structural identity to the enamel prisms.
- An organic matrix or prism sheath surrounds individual crystals.
- The spacing and orientation of the crystals and the amount of organic matrix make the enamel rod boundary and the central core differentially soluble when exposed for a short time to weak acids.



- The acid- treated enamel surface has an irregular and pitted surface with numerous microscopic undercuts, the etched enamel has a **higher surface energy**, so resin monomer flows into and adheres to the etched depressions to polymerize and form retentive resin tags.
- Because there are (30,000) to (40,000) enamel rods/ mm² and acid etch penetration increases the bondable surface area to (10) to (20) folds, micromechanical bonding of resin restorative materials to E. is significant.
- Acid-etch modification of enamel for restoration retention provides a conservative, reliable, alternative to traditional methods of tooth preparation and restorations (retentive grooves, pins, extension for prevention...).



- Starting at **1mm** from the CEJ, the rods on the vertical surfaces run occlusally or incisally at approximately a **60** degree inclination and progressively incline approaching the marginal ridges and cusp tips, where the rods are parallel to the long axis of the crown.
- The rods beneath the occlusal fissures are also parallel to the log axis, but rods on each side of the fissure vary up to **20** degrees from the long axis.
- In the cervical region of permanent teeth enamel rods are oriented outward in a slightly apical direction, therefore a perpendicular cut to the external surface of occlusal walls of preparation on axial surfaces compromised enamel, so an obtuse enamel Cavo-surface angle is recommended to closely parallel the rod direction and preserve the integrity of enamel margin.



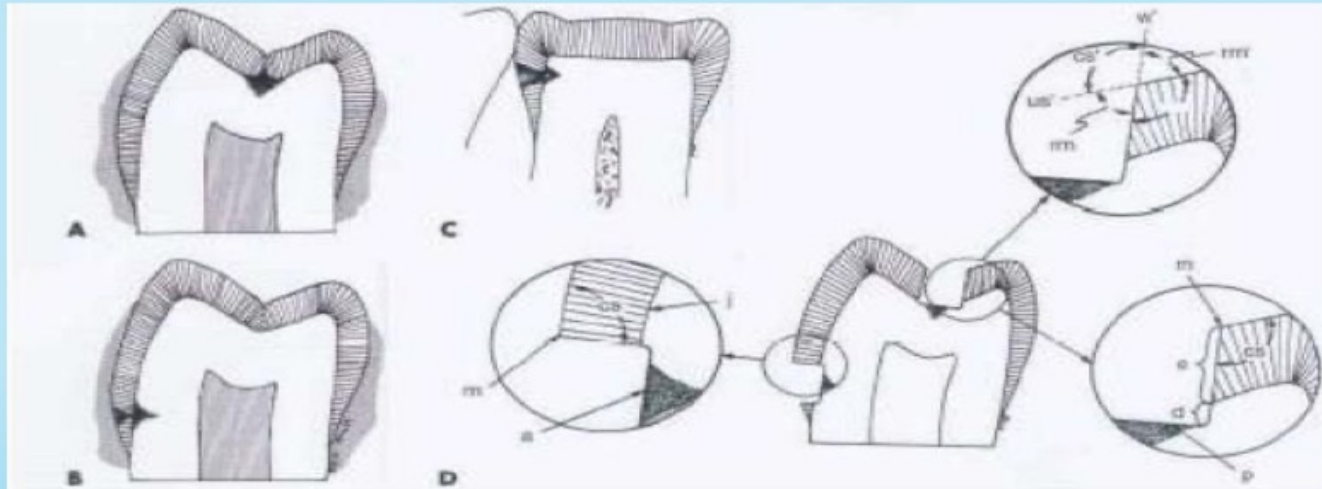


FIG. 6-2 Graphic example of cones of caries (decay) in pit and fissure of tooth (A) and on facial (B) and proximal (C) surfaces when caries has penetrated approximately same depth into dentin. Note differences in loss of enamel on external surfaces. D, Sectional view of initial stage of tooth preparations for lesions in A and B showing cavosurface angle (cs); axial wall (a); pulpal wall (p); enamel wall (e); dentinal wall (d); margin (m); and dentinoenamel junction (j). Note in upper exploded view that cavosurface angle (cs) can be visualized by imaginary projections (w') of the



Backward caries

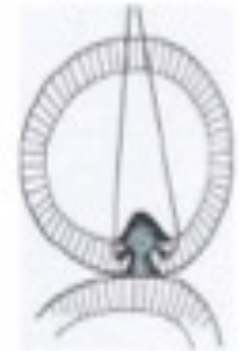

FIG. 6-3 Backward caries extends from DEJ into enamel.

- Loss of enamel rods that form the cavity wall of Cavo-surface margin of dental restorations **creates** a gap defect, leakage of bacteria and their products that may lead to secondary caries.
- Therefore, a basic principle of cavity wall preparation is to bevel or parallel the direction of enamel rods and avoid undercutting them.

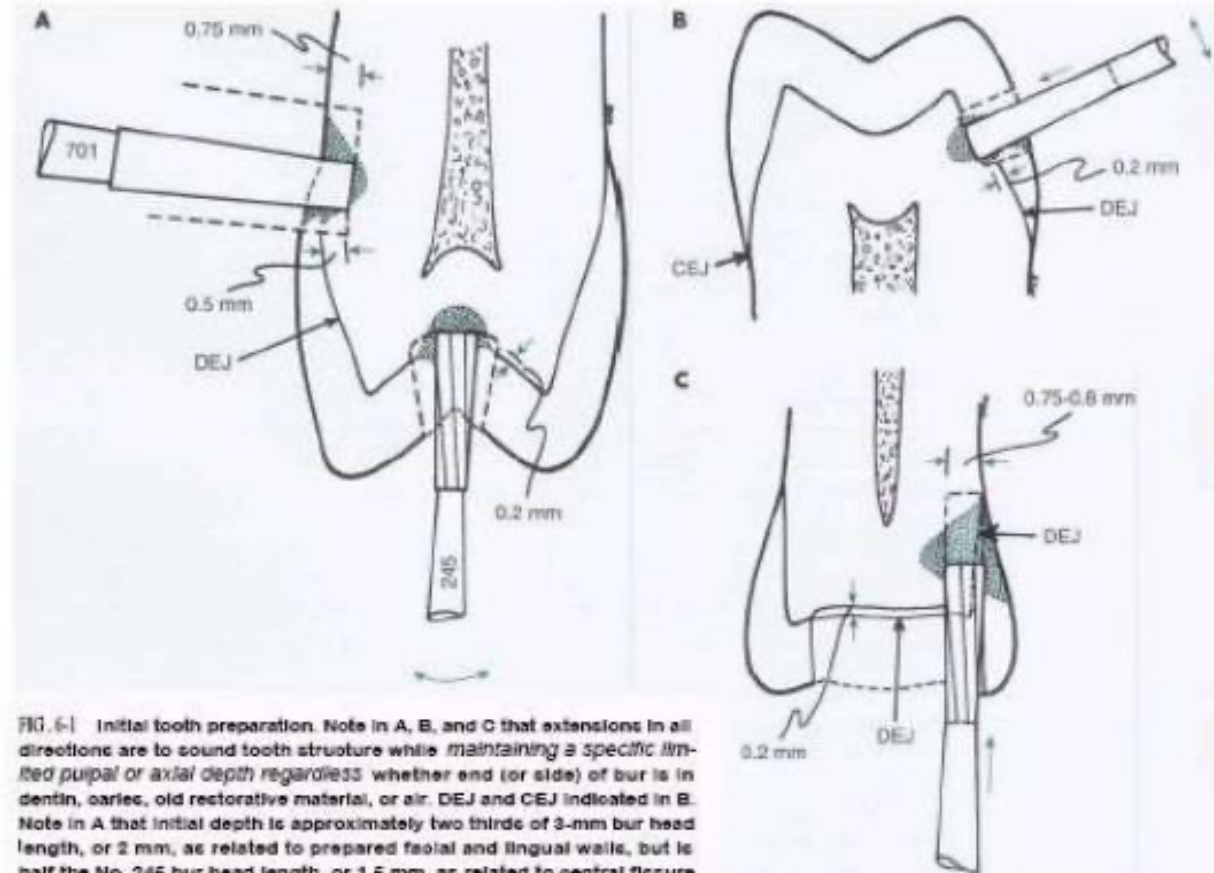
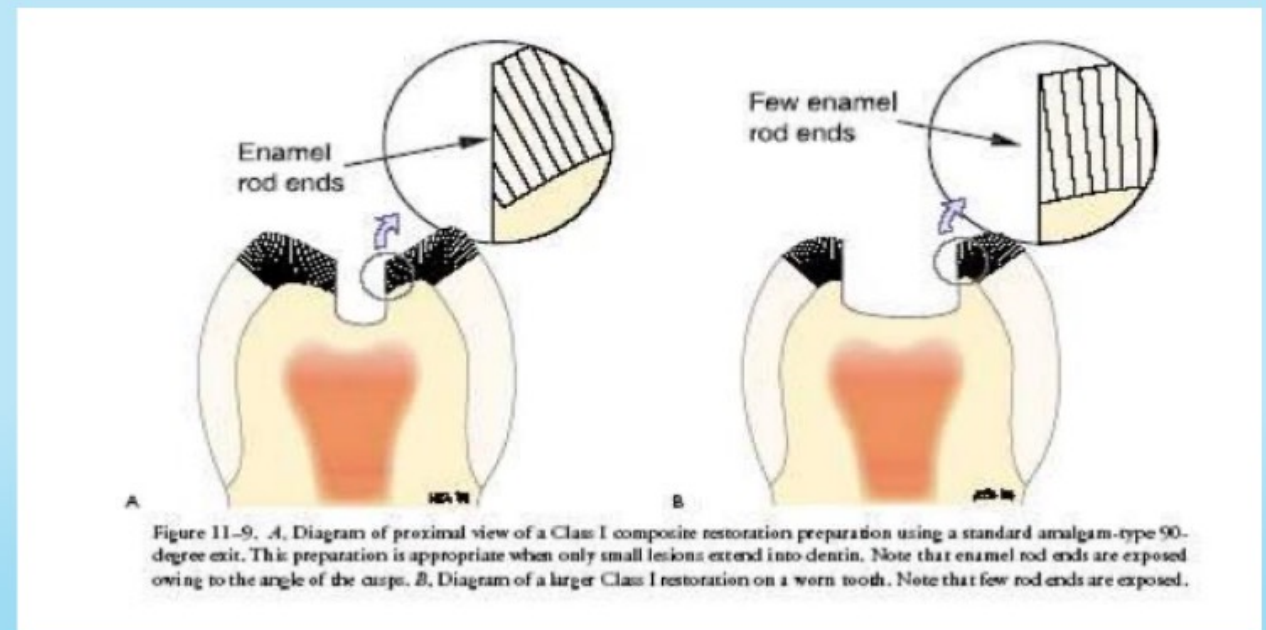


FIG. 6-1 Initial tooth preparation. Note in A, B, and C that extensions in all directions are to sound tooth structure while maintaining a specific limited pulpal or axial depth regardless whether end (or side) of bur is in dentin, caries, old restorative material, or air. DEJ and CEJ indicated in B. Note in A that initial depth is approximately two thirds of 3-mm bur head length, or 2 mm, as related to prepared facial and lingual walls, but is half the No. 246 bur head length, or 1.5 mm, as related to central fissure location.

- Understanding enamel orientation is very important in restorative dentistry, because enamel unsupported by underlying dentin is prone to fracture.



- Properties of Enamel

1. Hardness

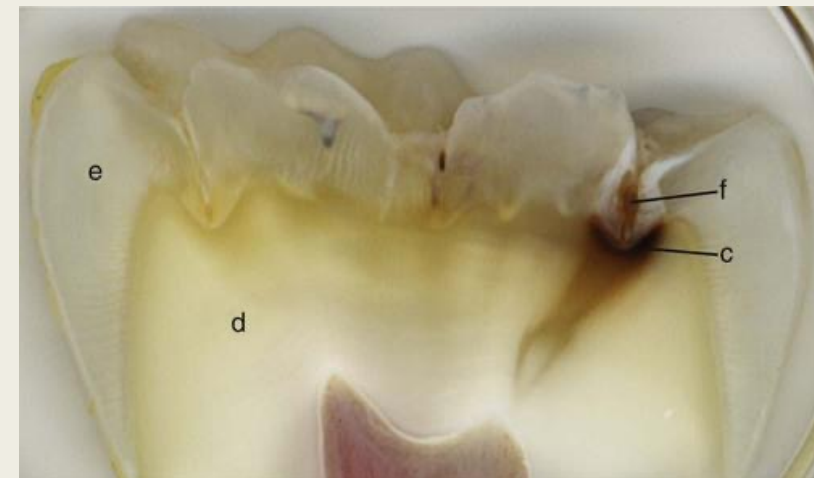
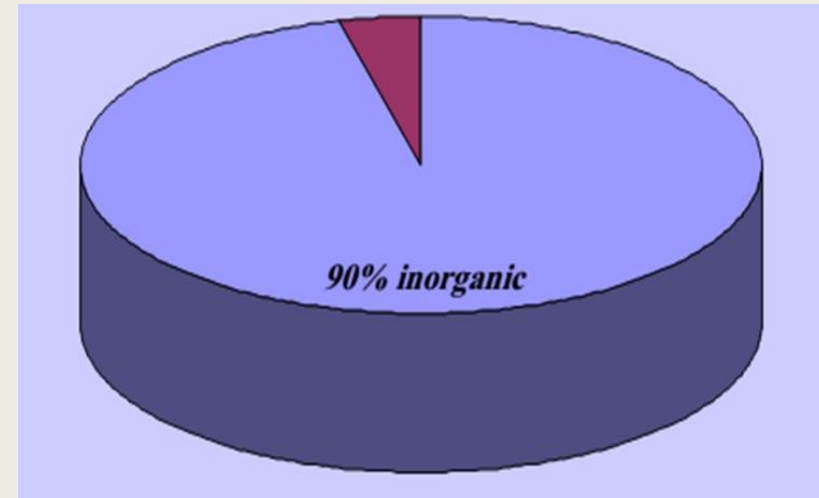
- Enamel is the hardest substance of human body.
- It is as hard as steel with a Knoop Hardness Number (KHN) of **343** (compared to **68** for dentin).
- However, enamel will wear because of attrition or frictional contact against opposing enamel or harder restorative materials such as porcelain.
- The normal physiologic contact wear rate for enamel is **15 to 29** μm per year.

2. Brittleness

- Enamel is very brittle; thus, it requires a base of dentin to withstand the masticatory stress.
- Enamel rods that fail to possess a dentin base because of caries or improper cavity design are easily fractured away from neighboring rods.

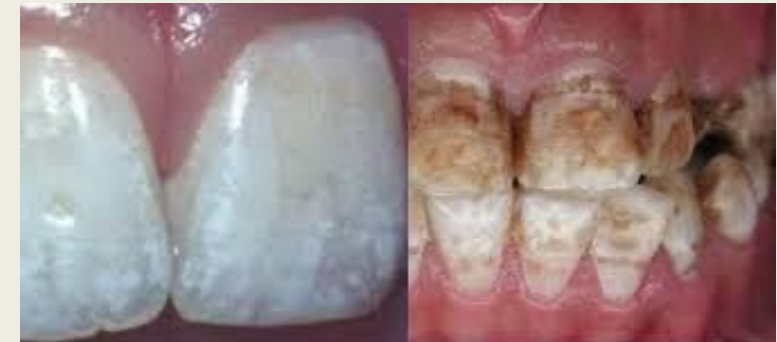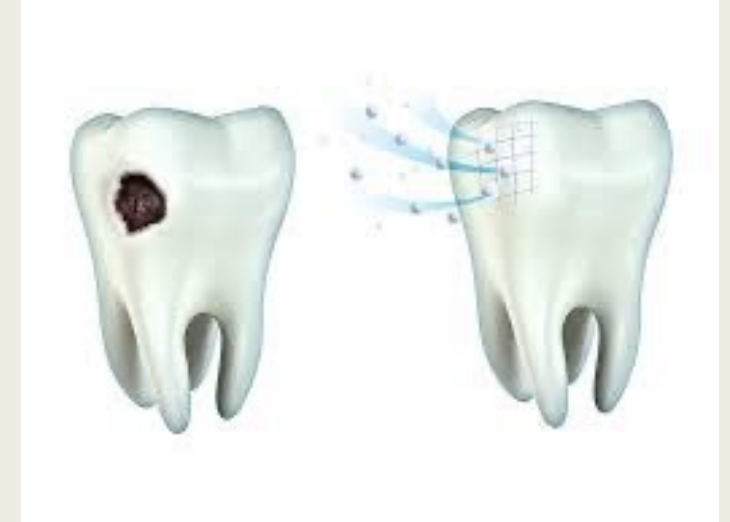
3. Permeability

- At maturity, enamel is about **90%** inorganic hydroxyapatite mineral by volume.
- Enamel also contains a small amount of organic matrix and **4%** to **12%** water which is contained in the intercrystalline spaces and in a network of micropores opening to the external surface.
- The micropores form a dynamic connection between the oral cavity and the systemic pulpal and dentinal tubule fluids.
- Various fluids, ions and low molecular weight substance can diffuse through the semipermeable enamel.
- Therefore, the dynamics of acid demineralization, caries, remineralization, fluoride uptake are not limited to the surface but are active in three dimensions.



4. Solubility to acids

- Enamel is soluble when exposed to acid medium, although the dissolution is not uniform.
- Solubility of enamel increases from the enamel surface to the dentinoenamel junction.
- When fluorides are present during enamel formation or are topically applied to the enamel surface, the solubility of surface enamel is decreased.
- Fluoride concentration decreases toward the dentinoenamel junction.
- Fluoride additions can affect the chemical and physical properties of the apatite mineral and influence the hardness, chemical reactivity, and stability of enamel while preserving the apatite structures.
- Trace amounts of fluoride stabilize the enamel by lowering acid solubility, by decreasing the rate of demineralization, and by enhancing the rate of remineralization.



5. Color

- Enamel is relatively *translucent*.
- It has a glossy surface and varies in color from *light yellow* to *grayish white*.
- Therefore, the color of the tooth is primarily a function of *the color of underlying dentin, enamel thickness* and *the amount of the stain in the enamel*.
- The thickness of enamel is greater at *the cusps tips* (2.5mm) and *incisal edges* (2mm) and decreases *below deep fissures* and become thin *cervically at the junction with cementum*.

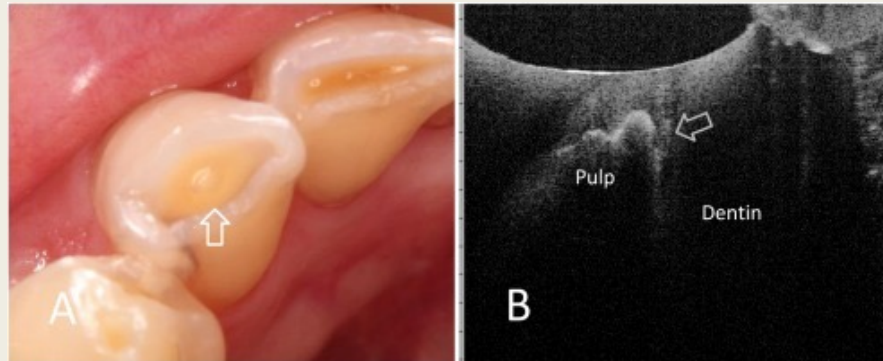
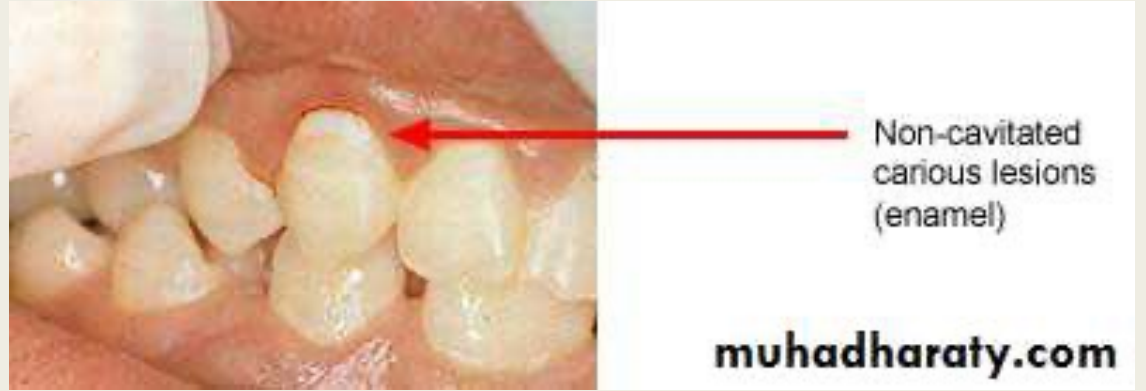
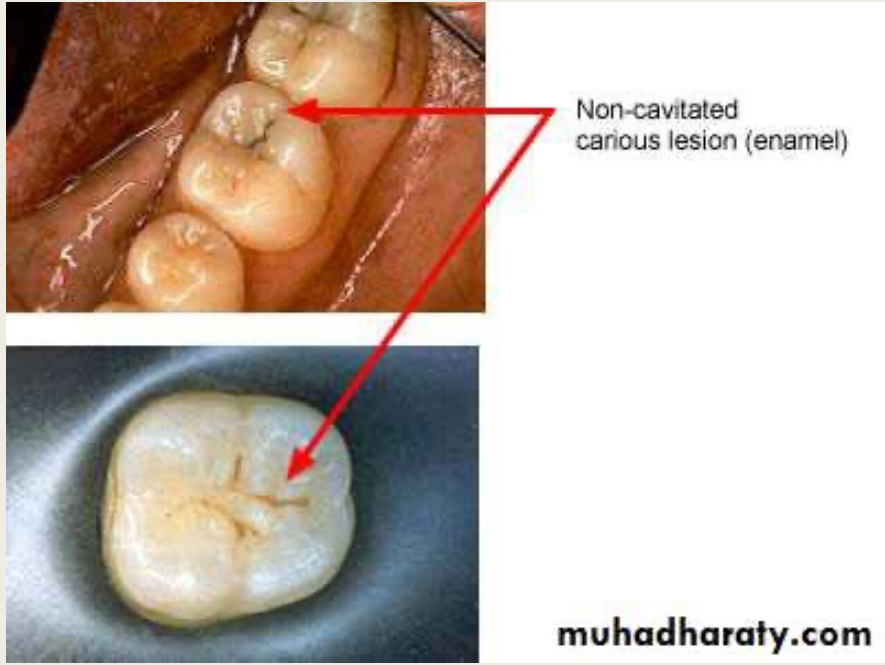
- The amount of translucency of enamel is related to *the variation in the degree of calcification and homogeneity*.
- Abnormal conditions of enamel usually result in *aberrant color*.
- Enamel becomes temporary whiter within minutes when the tooth is isolated from the moist oral environment by rubber dam or absorbents.
- Thus, the shade must be determined before isolation and preparation for a tooth - colored restoration.
- This change in color explained by the temporary loss of loosely bonded (or exchangeable) water (less than 1% by weight).

Clinical Appearance and Diagnosis:

- The dentist must pay close attention to the surface characteristics of E. for evidence of pathologic or traumatic conditions. Key diagnostic signs include:
 1. Color changes associated with demineralization
 2. Cavitation
 3. Wear
 4. Faults and fissures
 5. Cracks

1. *Color changes associated with demineralization*

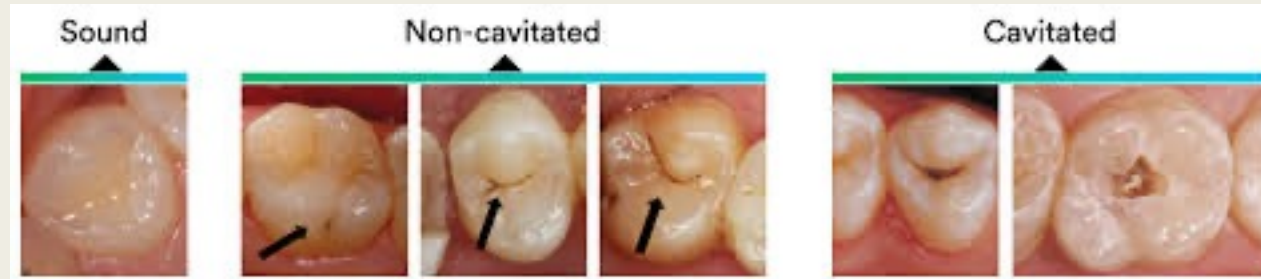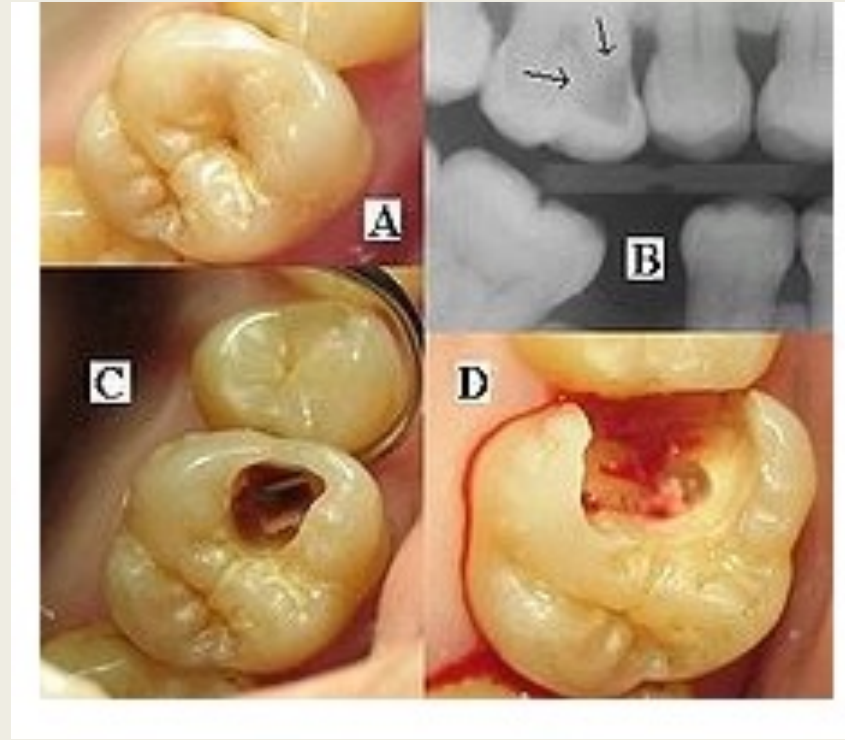
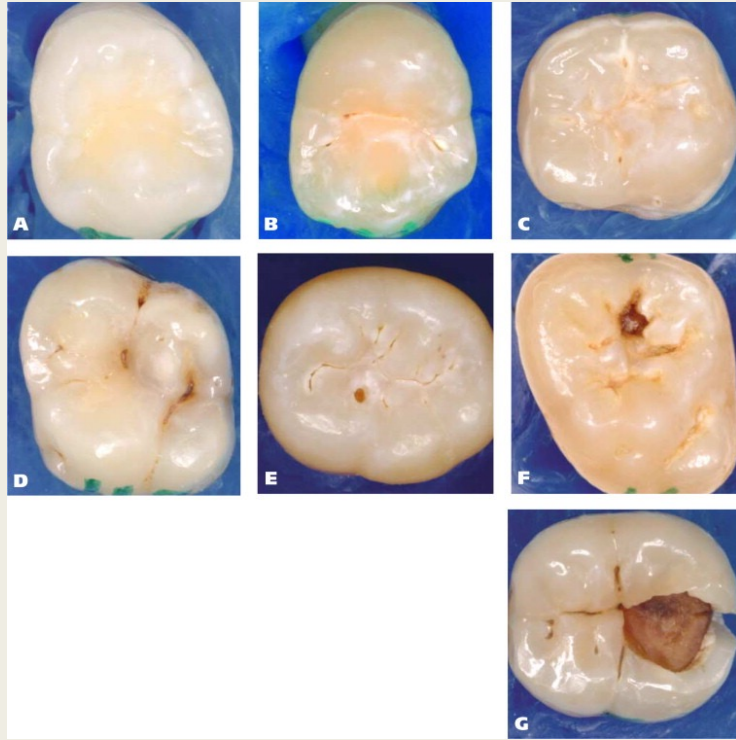
- Color changes related to enamel demineralization and caries are critical diagnostic observation.
- Subsurface enamel porosity from carious demineralization is manifested clinically by a milky white opacity called (**white spot lesion**); when located on smooth surfaces.
- In later stages of caries, internal demineralization of enamel at the **DEJ**, subsurface cavitation imparts a blue or gray color to the overlying enamel.















Caries in dentin

2. Cavitation

- The dentin is affected until enamel breaks away to create a cavity, a restoration must then be placed.
- If untreated the cavitation expands to compromise the structural strength of the crown and microorganisms infiltrate into deep dentin to affect the vitality of the tooth.
- When the carious lesion extends gingival to CEJ as in root caries, **isolation, access** and **gingival tissue response** complicate the restorative procedure.



Occlusal surface description	<ul style="list-style-type: none"> • White/brownish discoloration in the enamel visible after air-drying. • No cavitation. • No radiographic signs of caries 	<ul style="list-style-type: none"> • White/brownish discoloration in the enamel visible without air-drying. • Demineralisation located in the inner ½ of the enamel. • No radiographic signs of caries 	<ul style="list-style-type: none"> • Localized enamel breakdown without visible demineralisation in the dentine • No radiographic signs of dentine involvement 	<ul style="list-style-type: none"> • Underlying dark shadow from dentine • Carious lesion in the outer 1/3 of the dentine according to the radiograph 	<ul style="list-style-type: none"> • Distinct cavity with visible dentine • Carious lesion in the middle 1/3 of the dentine according to the radiograph 	<ul style="list-style-type: none"> • Considerable loss of tooth substance with possible pulpal involvement • Carious lesion in the inner 1/3 of the dentine according to the radiograph
Primary tooth						
Permanent tooth						

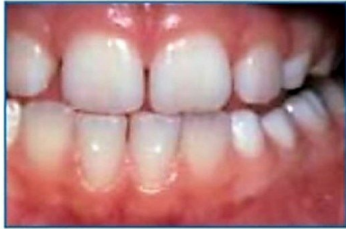3. Wear

- Enamel is as hard as steel. However, enamel will wear because of attrition or frictional contact against opposing enamel or harder restorative materials such as **porcelain**.
- Heavy occlusal wear is demonstrated when rounded cuspal contacts are ground to flat facets.
- Depending on factors such as **bruxism**, **malocclusion**, **age** and **diet**; cusps may be completely lost and enamel abraded away so that dentin is exposed.
- So, cavity outline form should be designed so that the margins of restorative materials avoid critical high stress areas of occlusal contact.

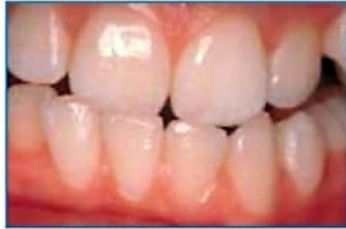

EMERALD DENTAL
SMILE PROTECTOR

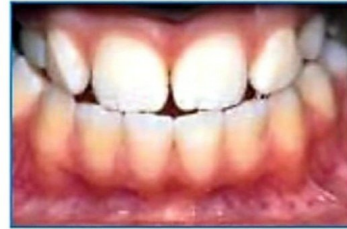www.emeralddental.in



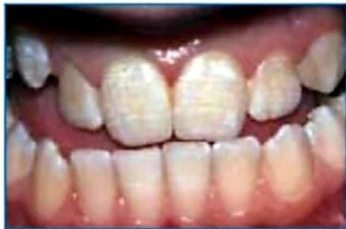Normal



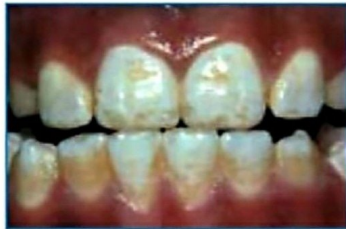Questionable



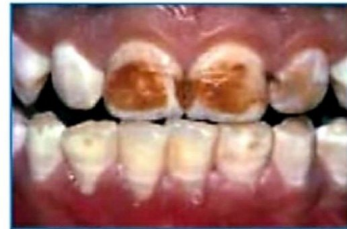Very mild



Mild



Moderate



Severe



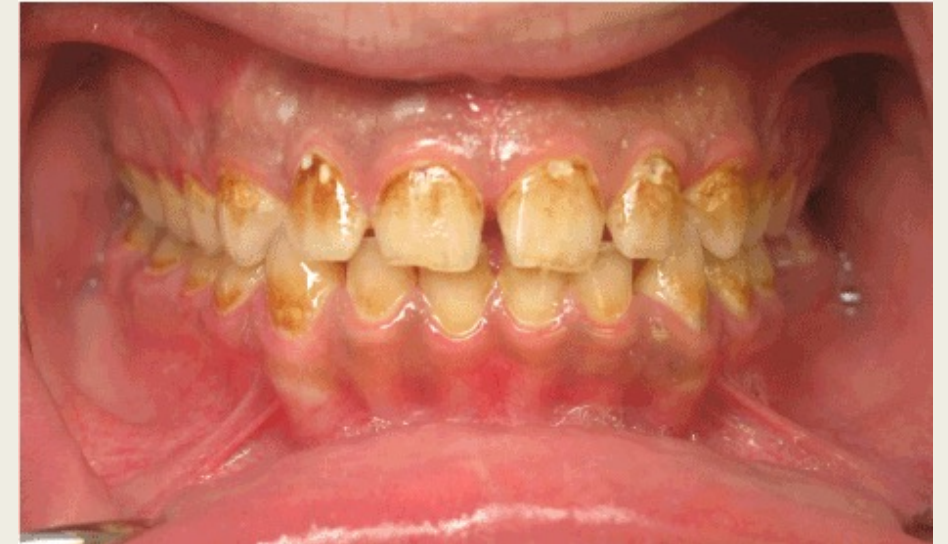[/ smileprotector](https://www.facebook.com/smileprotector)



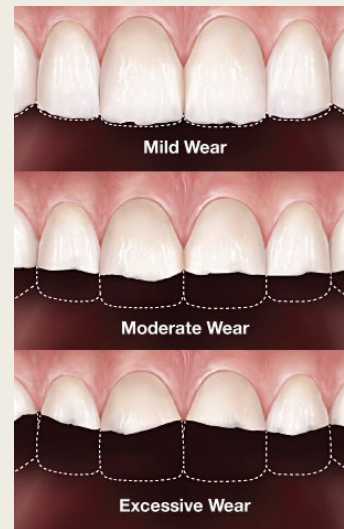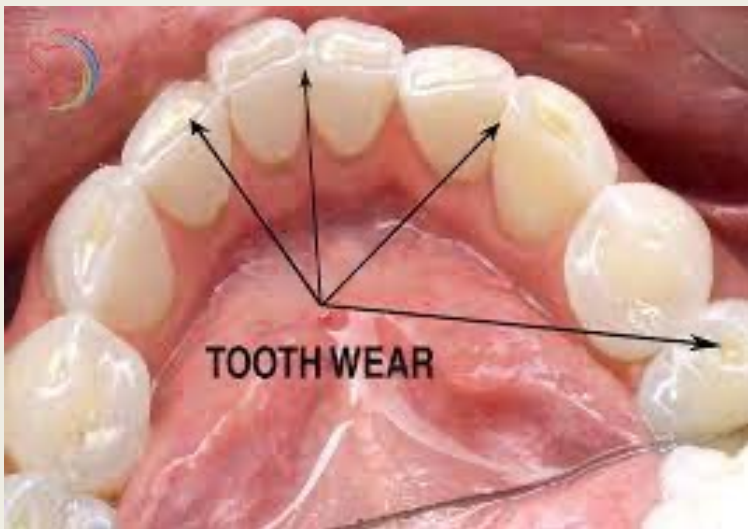[/ emeralddental.in](https://www.instagram.com/emeralddental.in)



[/ emeralddental2](https://twitter.com/emeralddental2)

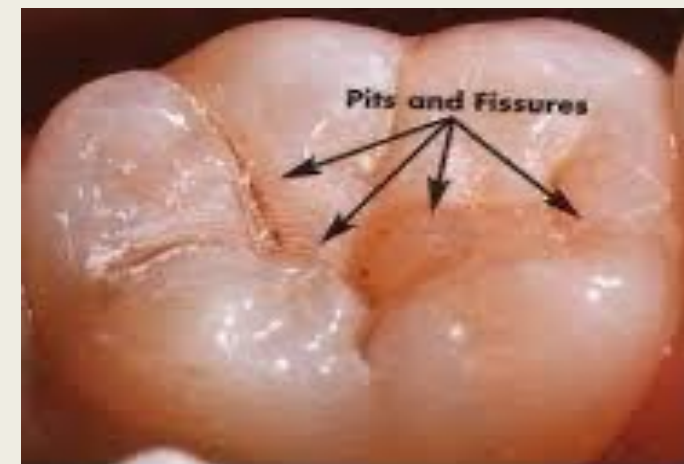


Moderate dental fluorosis



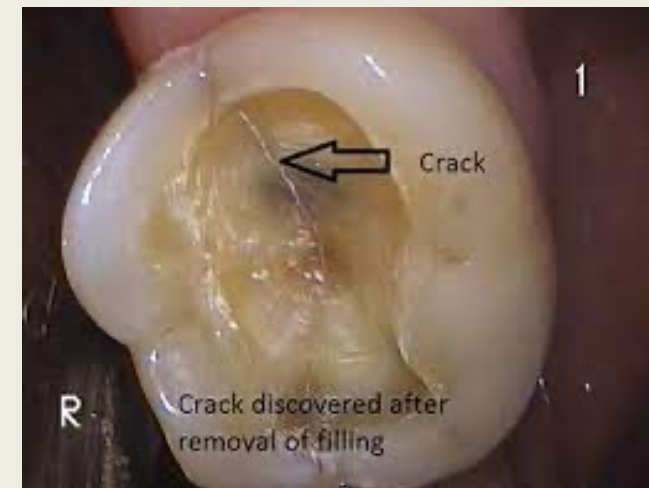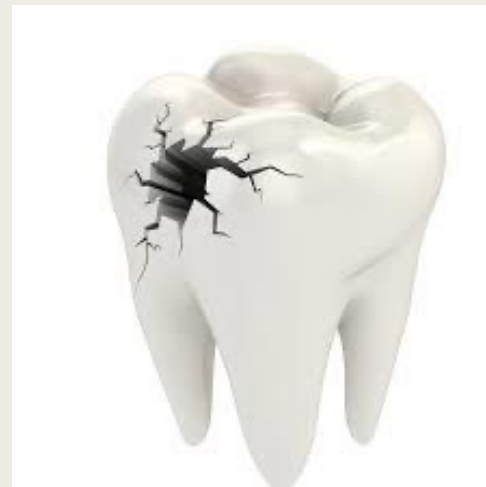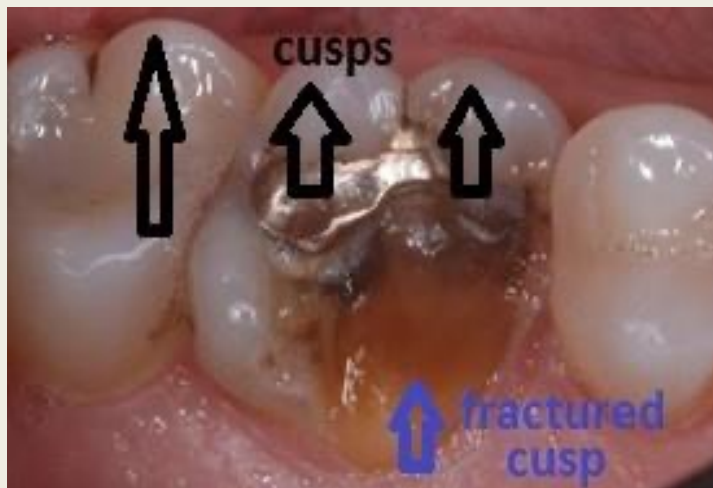
4. Faults and fissures

- A deep fissure is formed by *incomplete fusion of lobes of cuspal enamel in the developing tooth*.
- The resulting narrow clefts provide protected area for acidogenic bacteria.
- Pits and fissures defects are eight times more vulnerable to caries than are smooth surfaces.
- Careful observation of enamel surrounding fissures for evidence of demineralization or cavitations' is necessary to determine the need for restorative intervention.



5. Cracks

- Pronounced cracks that extend from developmental grooves across marginal ridges to axial walls or from the margins of large restorations may cause cuspal fracture.
- When this crack extends through dentin or when the patient has pain when chewing; the tooth requires a restoration that provide complete cuspal coverage.



Thank you

